

## CASE REPORT

# Bilateral radial head fractures in a martial arts athlete

N V Deshmukh, M S Shah

*Br J Sports Med* 2003;**37**:270–271

Isolated radial head fractures, which are rare, comprise about 2% of all fractures around the elbow. A case is reported of bilateral radial head fracture in an international female athlete. Early recognition and aggressive rehabilitation is essential if an abrupt end to a promising sporting career is to be prevented.

## CASE REPORT

While practising, a 19 year old international female tae kwon do athlete attempted to block a kick with her hands crossed and her elbows in extension. She presented with swollen, painful elbows. On clinical examination, the radial heads were found to be tender. Supination and pronation of the forearm was restricted on both sides. There was no neurovascular deficit. Radiographs showed a Mason I radial head fracture on both sides (fig 1). Both elbows were aspirated under sedation and full aseptic precautions. A 10–12 ml volume of frank blood was aspirated from both elbows; local anaesthetic was injected at the fracture site. Aggressive rehabilitation was begun as soon as the pain had settled. At the end of the eighth week, the patient had regained full range of movements of the elbow and the forearm, and three months after the injury she was back to her previous performance level, making a full recovery.

## DISCUSSION

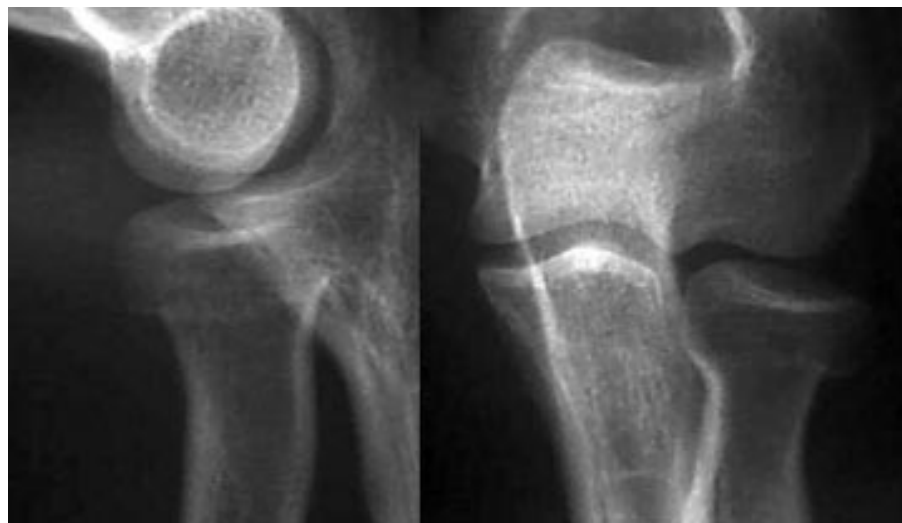
Bilateral radial head fracture is a very rare injury.<sup>1</sup> The usual mechanism is a fall on an outstretched hand with the elbow partly flexed and the forearm in supination. Anatomically the radial head is susceptible to fractures because of a 15° angle between the radial neck and shaft. With the forearm in pronation, the anterolateral margin of the radial head comes into contact with the capitellum and thus is susceptible to a shearing type of injury. Conventional posteroanterior, lateral,

and oblique radiographs of the elbow are adequate for detection of radial head fractures. Acute pain, local tenderness with associated swelling, and a positive fat pad sign with a fracture line are diagnostic features. Treatment options are based on the classification of Mason,<sup>2</sup> who subdivided radial head fractures into three groups:

- type I, undisplaced marginal fractures;
- type II, displaced marginal fractures;
- type III, comminuted fractures.

By definition, type I is an undisplaced fracture, requires no reduction, and does not exhibit any mechanical block to forearm rotation. Immediate pain relief should be achieved to allow initial physical examination and to start active forearm rotation as pain allows. Type I injuries should be treated conservatively as in this case. Joint aspiration of haemarthrosis and injection of an anaesthetic into the joint may be performed to reduce pain. The landmarks for aspiration of the elbow joint are the radial head, lateral epicondyle, and tip of the olecranon. A needle inserted into the centre of the triangle penetrates only the anconeus muscle and capsule before entering the joint. A sling for the first week of treatment is necessary to control the inflammatory phase. Early range of motions is advocated, peaking one week after the fracture, to prevent long term limitation of movement, particularly loss of full extension of the elbow. Mezera and Hotchkiss<sup>3</sup> state that Mason type I fractures have an excellent prognosis. Residual elbow contracture, pain, and occasionally displacement of the fracture have been reported in a few patients.

Mason and Shutkin<sup>4</sup> suggested that early mobilisation allows the fragment to find the best functional position in relation to the other joint surfaces. Bakalim<sup>5</sup> showed that displacement of the fragment was not associated with loss of function. Postlethwaite,<sup>6</sup> Gaston *et al*,<sup>7</sup> and Quigley<sup>8</sup> have also suggested aspiration of the haemarthrosis after radial head fractures.



**Figure 1** Radiographs showing Mason I radial head fractures.

### Take home message

The importance should be stressed of early recognition, elbow aspiration, intra-articular injection of anaesthetic, early mobilisation (second or third day after injury), and aggressive rehabilitation in patients with a radial head fracture, which could make the difference between the end of a promising career and a gold medal.

Fleetcroft<sup>9</sup> reported a prospective study with a two year follow up. Patients in the aspirated group had earlier relief of pain and return of function, a significant difference was found between the two groups. There was sustained impairment of movement in the non-aspirated elbows at final follow up in this study.

Holdsworth *et al*<sup>10</sup> conducted a prospective control study and concluded that functional recovery was best in younger patients and was closely related to the severity of the fracture. They showed that a delay in restoration of early active movement led to a delay in the recovery of function. They stated that aspiration of the elbow is a quick, safe, and painless procedure, which greatly reduces discomfort to the patient and allows early return of movement of the elbow.

Dooley and Angus<sup>11</sup> performed a prospective study of elbow aspiration in type I and type II fractures of the radial head. Aspiration of the haemarthrosis from the elbow produced dramatic pain relief in 77% of cases. Earlier return to function was also noted in these elbows. They recommended elbow aspiration for patients with radial head fractures for relief of pain and restoration of early function.

Carley<sup>12</sup> suggested that a properly designed prospective controlled trial should be carried out, and pain, mobility, time of healing, and infection rate should be looked at. He suggested that aspiration may benefit patients with traumatic elbow effusions and that the evidence was insufficient to recommend it as a routine procedure.

Our patient had a type I radial head fracture and was mobilised as soon as the pain subsided on the second day after injury even though the elbow was swollen and bruised on the lateral aspect. After two months, she had made a complete recovery with full range of motion and had resumed her taekwon do activities after three months. At the final review after two years, she had no residual symptoms from her injury.

### Authors' affiliations

**N V Deshmukh, M S Shah**, Department of Orthopaedics, Witherby NHS Trust, Pembrokeshire, Wales, UK

Correspondence to: Dr Deshmukh, 8 Albert Street, Haverfordwest, Pembrokeshire SA61 1TB, UK; deshmukh\_nitin@hotmail.com

Accepted 9 August 2002

### REFERENCES

- 1 **Hodge JC**. Bilateral radial head and neck fractures. *J Emerg Med* 1999;**17**:877–81.
- 2 **Mason ML**. Some observations on fractures of the radial head with a review of one hundred cases. *Br J Surg* 1954;**42**:123.
- 3 **Mezera K**, Hotchkiss RN. Fractures of the radial head. In: *Rockwood & Green's fractures in adults*. Philadelphia: JB Lippincott, 2001;**1**:940–51.
- 4 **Mason JA**, Shutkin NM. Immediate active mobilisation in the treatment of fractures of the head and neck of the radius with a review of one hundred cases. *Surg Gynecol Obstet* 1943;**76**:731–7.
- 5 **Bakalim G**. Fractures of the radial head and their treatment. *Acta Orthop Scand* 1970;**41**:320–31.
- 6 **Pastlathwaite RW**. Modified treatment of fractures of the radial head. *Am J Surg* 1945;**67**:77–80.
- 7 **Gaston SR**, Smith FM, Baab OD. Adult injuries of the radial head and neck. *Am J Surg* 1949;**78**:631–5.
- 8 **Quigley JB**. Aspiration of the elbow joint in the treatment of fractures of the head of radius. *N Engl J Med* 1949;**240**:915–16.
- 9 **Fleetcroft JP**. Fractures of radial head. Early aspiration and mobilisation. *J Bone Joint Surg [Br]* 1984;**66**:141–2.
- 10 **Holdsworth BJ**, Clement DA, Rothwell PNR. Fractures of the radial head: the benefit of aspiration: a prospective controlled trial. *Injury* 1987;**18**:44–7.
- 11 **Dooley JF**, Angus PD. The importance of elbow aspiration when treating radial head fractures. *Arch Emerg Med* 1991;**8**:117–21.
- 12 **Carley S**. The role of therapeutic needle aspiration in radial head fractures. *Journal of Accident and Emergency Medicine* 1999;**16**:282.

### COMMENTARY

This is a timely review of Mason I radial head fractures, with an excellent review of the literature on aspiration of the haemarthrosis in this injury which benefits the outcome.

There is no doubt that Mason I fractures are treated in a variable fashion. Many doctors assume that immobilisation is the only option, and immobilise for too long for the good of the elbow. Other surgeons see the patient with stiffness and assume biomechanical failure, and therefore openly reduce.

This article reviews the literature supporting early intervention by aspiration and early mobilisation. These two simple techniques avoid most of the complications associated with this fracture, and allow most patients to return to sport early and well. The fact that Carley has downgraded the evidence to date does not mean the procedure is not efficacious, and I would support the authors' conclusion.

**G Hoy**

Hand and Upper Limb Surgeon, Melbourne Orthopaedic Group, 33 The Avenue, Windsor, Victoria 3181, Australia