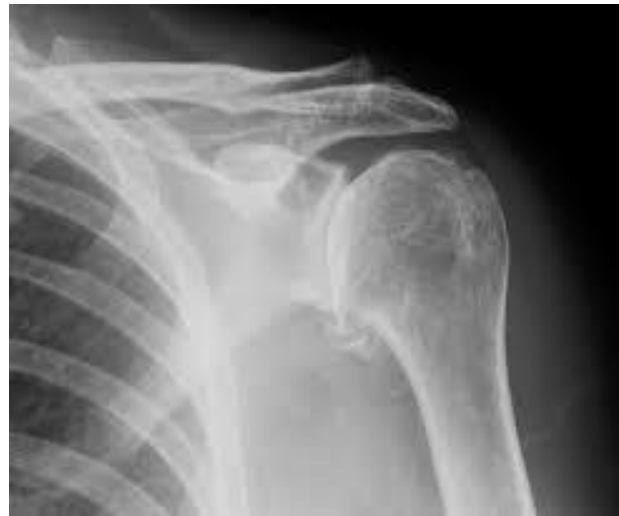


Rationale Of Arthroplasty



Munawar Shah





Rationale Of Arthroplasty

What is available


What is Evidence

What Do I do

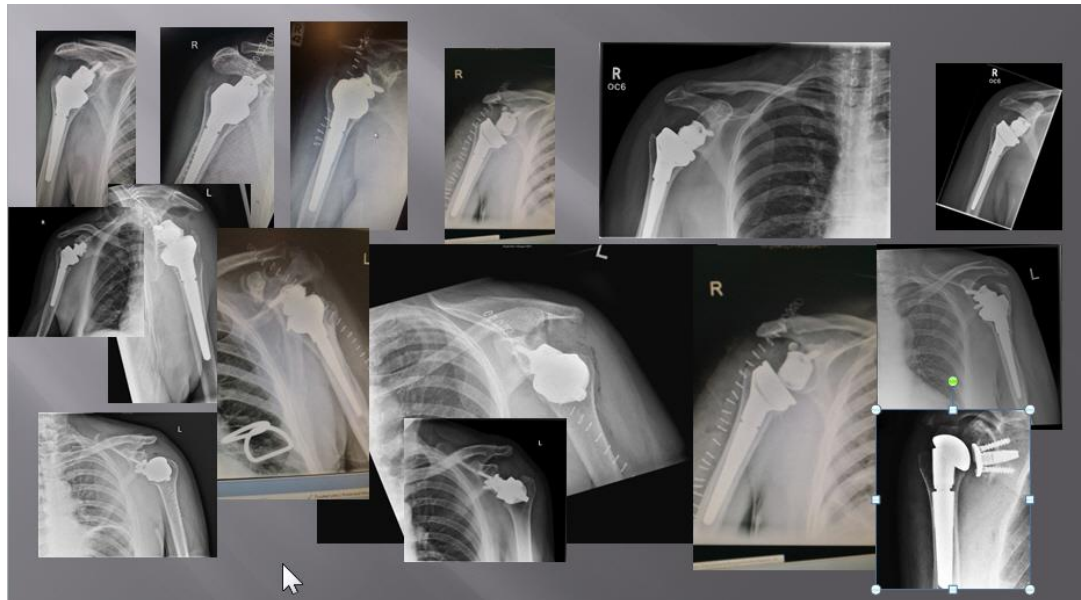


Munawar Shah






Rationale Of Arthroplasty



Munawar Shah






Rationale Of Arthroplasty

The primary goal of shoulder replacement surgery is pain relief, with a secondary benefit of restoring motion, strength, function, and assisting with returning patients to an activity level as near to normal as possible.

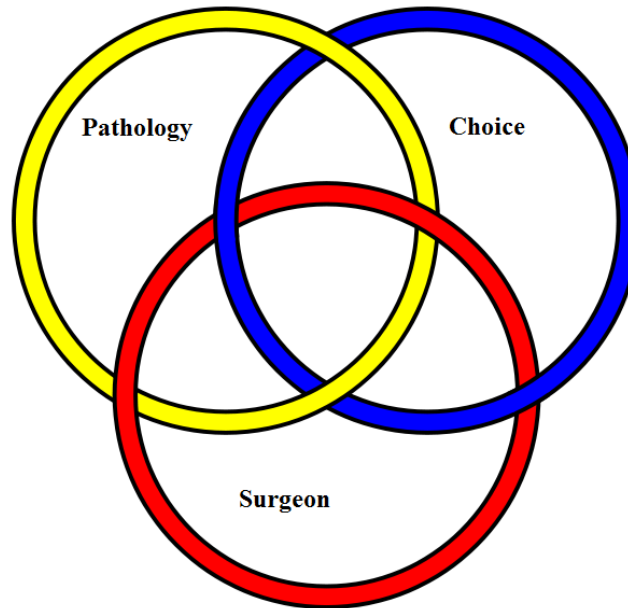


Munawar Shah






Rationale Of Arthroplasty



Munawar Shah






Rationale Of Arthroplasty

**Cemented/Cementless
Stem/Stemless
Total/Hemi**

Munawar Shah





Rationale Of Arthroplasty

Trauma/Degenerative

Young/Old


Osteo/Inflammatory arthritis AVN

Revision

Tumour/Infection

Munawar Shah






Rationale Of Arthroplasty

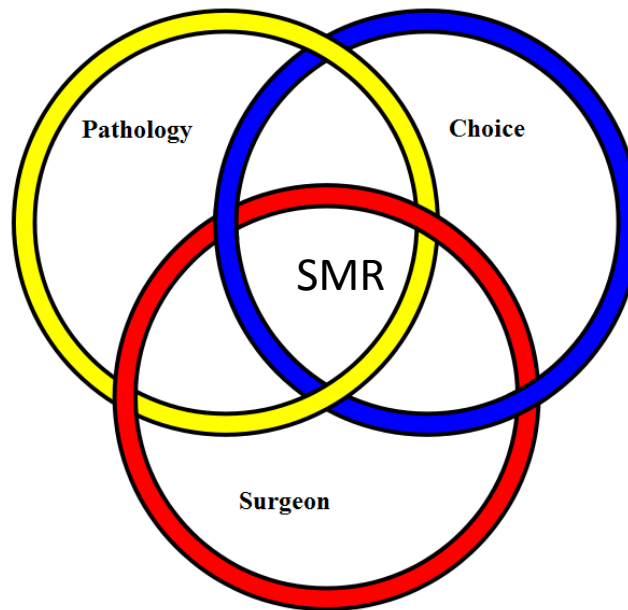
Stem/Stemless
Cement/Cementless/Tribology
Monoblock/Modular
Hemi/Anatomic/Reverse
Platform System

Munawar Shah






Rationale Of Arthroplasty



Munawar Shah






Rationale Of Arthroplasty

What is available



Munawar Shah





Rationale Of Arthroplasty


Today, there are more than 70 different shoulder systems on the market.

Surgeon must examine each patient carefully in making that final decision as to which one to choose.



Munawar Shah





Rationale Of Arthroplasty

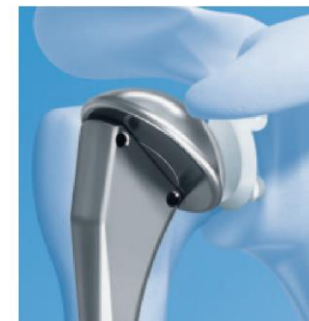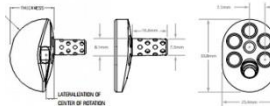


equinox
Platform
Shoulder System




GLENOSPHERE/GLENOID PLATE

	Diameter	Thickness	Average Lateralization of Center of Rotation
38 Glenosphere	38	23.1	2
42 Glenosphere	42	25.1	
46 Glenosphere	46	27.1	

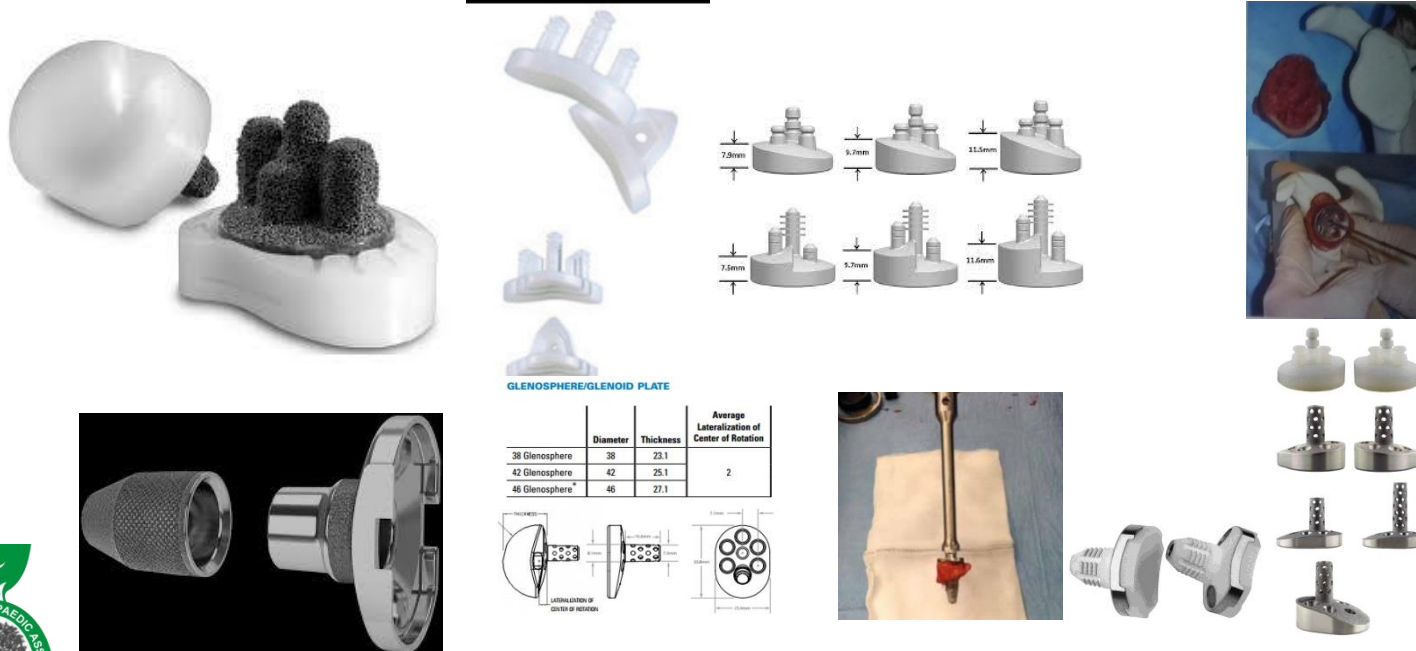


Munawar Shah






Rationale Of Arthroplasty

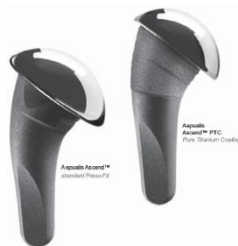

Munawar Shah






Rationale Of Arthroplasty



Munawar Shah






Rationale Of Arthroplasty

What is the evidence



Munawar Shah





Rationale Of Arthroplasty


*Carlo Felice De Biase, Bone Joint J 2013
vol. 95-B no. SUPP 15 50*

**using a fully modular system from the first implant
allows skipping the humeral stem removal/
reimplantation step in cases of conversion from a
shoulder prosthesis to a reverse with good clinical results**



Munawar Shah





Rationale Of Arthroplasty


*K. Mohammed and A. Slaven, JBJS Br
Volume 2012*

**These results confirm that reliable medium term
osteointegration does occur with the SMR metal back
Glenoid in anatomical total shoulder replacement.**



Munawar Shah





Rationale Of Arthroplasty


*Castagna A, SECEC-ESSSE 2012 Sep
19–22; Dubrovnik, Croatia.*

**It Was concluded that press- fit humeral stem is stable
option in shoulder Arthroplasty.**



Munawar Shah





Rationale Of Arthroplasty


J.A. Delgado, J Bone Joint Surg 2011

**Authors treated 50 patients with complex proximal humeral fractures with a reverse shoulder Arthroplasty.
The Results were excellent**



Munawar Shah





Rationale Of Arthroplasty


Boyle MJ, JSES2013

Patients with acute proximal humeral fractures who undergo RSA appear to achieve superior 5-year functional outcomes compared with patients who undergo hemiarthroplasty.



Munawar Shah





Rationale Of Arthroplasty


A.A. Martinez, J Orthop Sci 2012

The reverse total shoulder Arthroplasty improves function and motion in patients with proximal humeral fracture sequelae



Munawar Shah






Rationale Of Arthroplasty



Munawar Shah






Rationale Of Arthroplasty



Munawar Shah





Rationale Of Arthroplasty

Shoulder hemiarthroplasty: review of basic concepts


A.M. Foruria, S. Antuña and E.C. Rodríguez-Merchán
Department of Orthopedic and Trauma Surgery. La Paz University Hospital. Madrid. Spain.

shoulder hemiarthroplasty has led to satisfactory, reproducible and lasting results in addressing conditions like glenohumeral arthritis, avascular necrosis and rheumatoid arthritis



Munawar Shah






Rationale Of Arthroplasty

What is my practise



Munawar Shah





Rationale Of Arthroplasty

Intraoperative Versility


Efficient management of The evolution of Pathology

Easy Conversion




Munawar Shah





Munawar Shah






Rationale Of Arthroplasty



Munawar Shah






Rationale Of Arthroplasty



Munawar Shah





Rationale Of Arthroplasty



GLENOID

Available in 4 sizes which, combined with a proven clinical performance, offer a comprehensive solution for glenoid implants

REVERSE HP WITH X-LIMA POLYETHYLENE GLENOSPHERES

Large diameters of 40 mm and 44mm and the inversion of the materials ensure high stability and scapular notch prevention




36mm METAL GLENOSPHERE

Choose between Standard and Eccentric versions

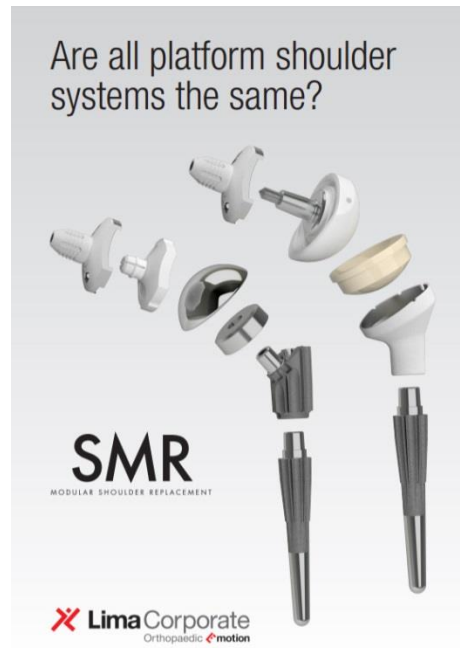

Munawar Shah






Rationale Of Arthroplasty



Munawar Shah





Rationale Of Arthroplasty


Intraoperative Choice?

SMR provides an intuitive set of instrumentation

2 trays for Hemi Arthroplasty


3 trays for Total Shoulder Arthroplasty

3 trays for Reverse Shoulder Arthroplasty



Munawar Shah





Rationale Of Arthroplasty

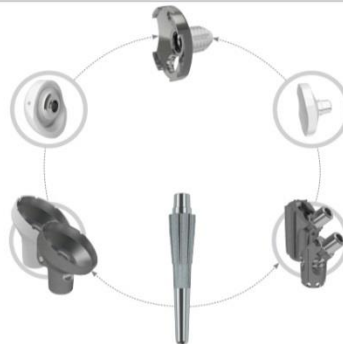
Humeral and Glenoid Modularity

Unique distally fixed stem and metal backed glenoid

Proven stable fixation on both sides


Intraoperative choice

Simplified revision



Munawar Shah






Rationale Of Arthroplasty



Munawar Shah




Rationale Of Arthroplasty



Munawar Shah






Rationale Of Arthroplasty



Munawar Shah




Rationale Of Arthroplasty



Munawar Shah





Rationale Of Arthroplasty

Reverse Shoulder Arthroplasty

Higher function notch reducing options

40 mm and 44 mm HP
polyethylene spheres reduce
notching while providing better
stability and range of motion

Oval metal back glenoid design
provides simple technique


Ceramic humeral liner options
reduces wear and nickel sensitivity



REVERSE **HP**

Munawar Shah





Rationale Of Arthroplasty

Humeral Fracture Solutions

Anatomical or reverse its your choice

Good tuberosity fit to
small proximal body

Cementless and cemented
stem options


Reverse body option
with suture 'ears'

Distally fixed stem allows
simpler revision in future

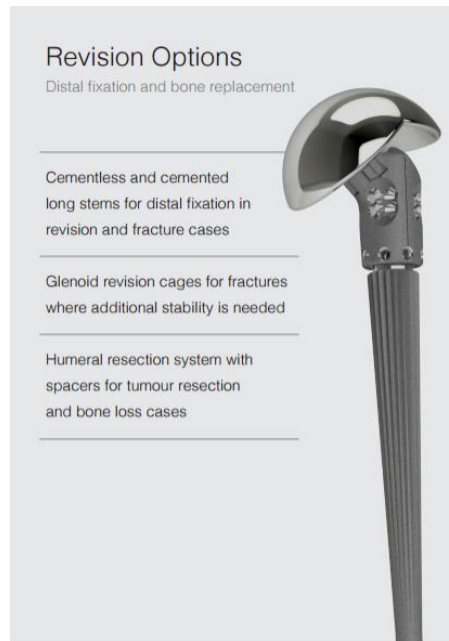


Munawar Shah






Rationale Of Arthroplasty

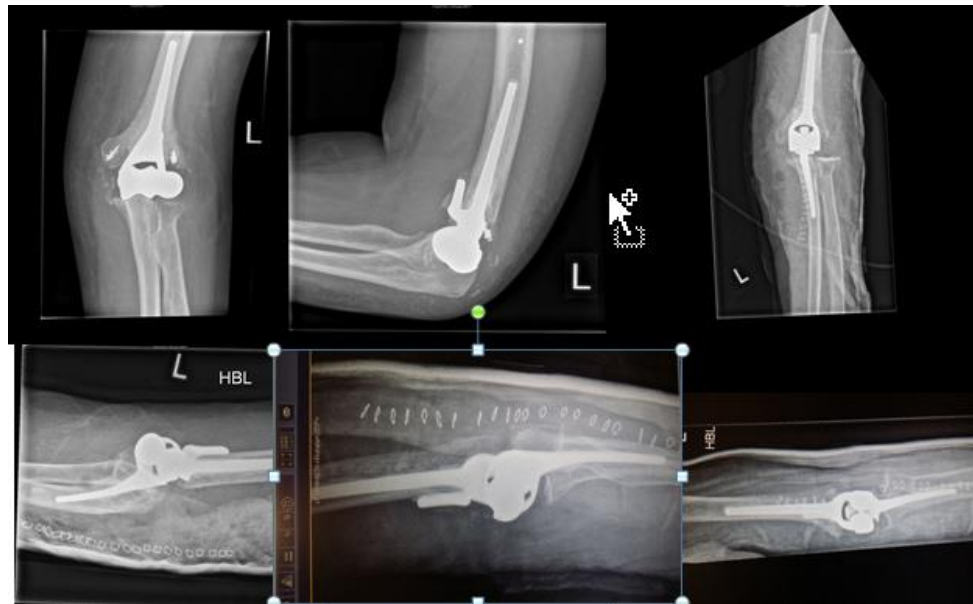

Munawar Shah






Rationale Of Arthroplasty



Munawar Shah






Rationale Of Arthroplasty

The primary goal of Elbow replacement surgery is pain relief, with a secondary benefit of restoring motion, strength, function, and assisting with returning patients to an activity level as near to normal as possible.

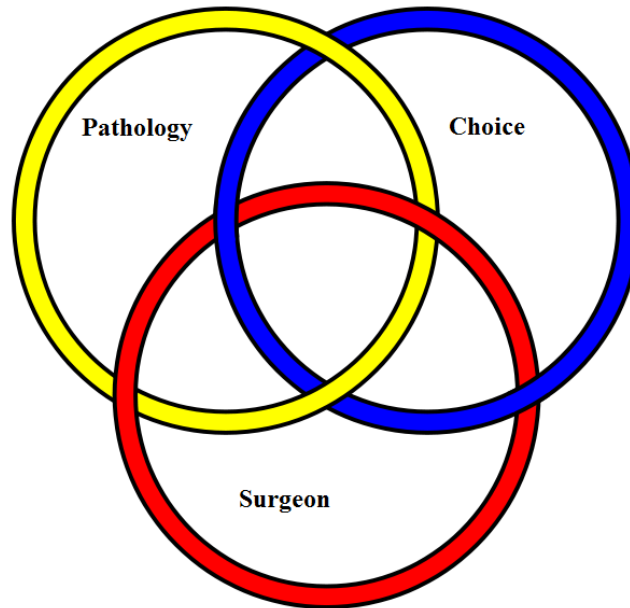


Munawar Shah






Rationale Of Arthroplasty



Munawar Shah






Rationale Of Arthroplasty

**Modular
Total/Hemi
Constrained/Unconstrained
Platform System**

Munawar Shah





Rationale Of Arthroplasty

Trauma/Degenerative

Young/Old


Osteo/Inflammatory arthritis AVN

Revision

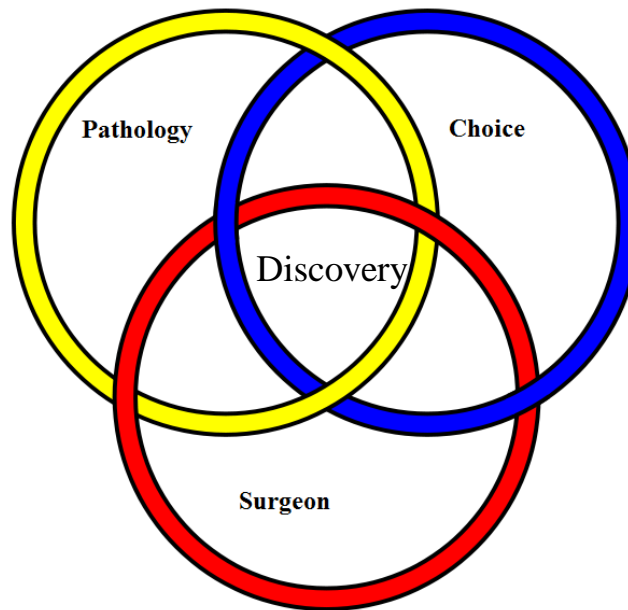
Tumour/Infection

Munawar Shah






Rationale Of Arthroplasty



Munawar Shah






Rationale Of Arthroplasty

What is available



Munawar Shah






Rationale Of Arthroplasty



Munawar Shah






Rationale Of Arthroplasty




Munawar Shah






Rationale Of Arthroplasty



Munawar Shah





Rationale Of Arthroplasty


Today, there are more than a few different elbow systems on the market.

Surgeon must examine each patient carefully in making that final decision as to which one to choose.



Munawar Shah






Rationale Of Arthroplasty

What is the evidence



Munawar Shah






Rationale Of Arthroplasty

Morrey et al and Stanley et al have published good outcome in inflammatory arthritis and Trauma in elderly

Gill DR, Morrey BF. The Coonrad-Morrey total elbow Arthroplasty in patients who have rheumatoid arthritis. A ten to fifteen-year follow-up study. J Bone Joint Surg Am. 1998;80(9):1327–35.

Munawar Shah





Rationale Of Arthroplasty


Sixty-nine elbows 9.1 years (range 2-20.5).

Sixteen primary Arthroplasty (19%) failed secondary to isolated bushing wear , infection , component fracture , or component loosening .

Schneeberger AG, Adams R, Morrey BF. Semiconstrained total elbow replacement for the treatment of post-traumatic osteoarthritis. J Bone Joint Surg Am. 1997;79(8):1211–22.

Munawar Shah






Rationale Of Arthroplasty

What is my practise

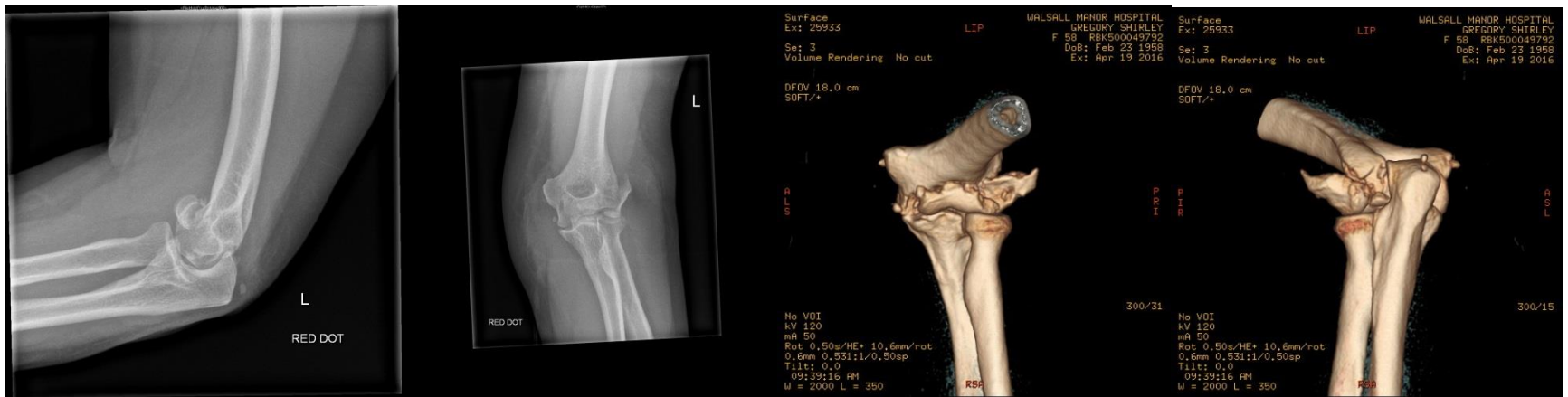

Munawar Shah






Rationale Of Arthroplasty

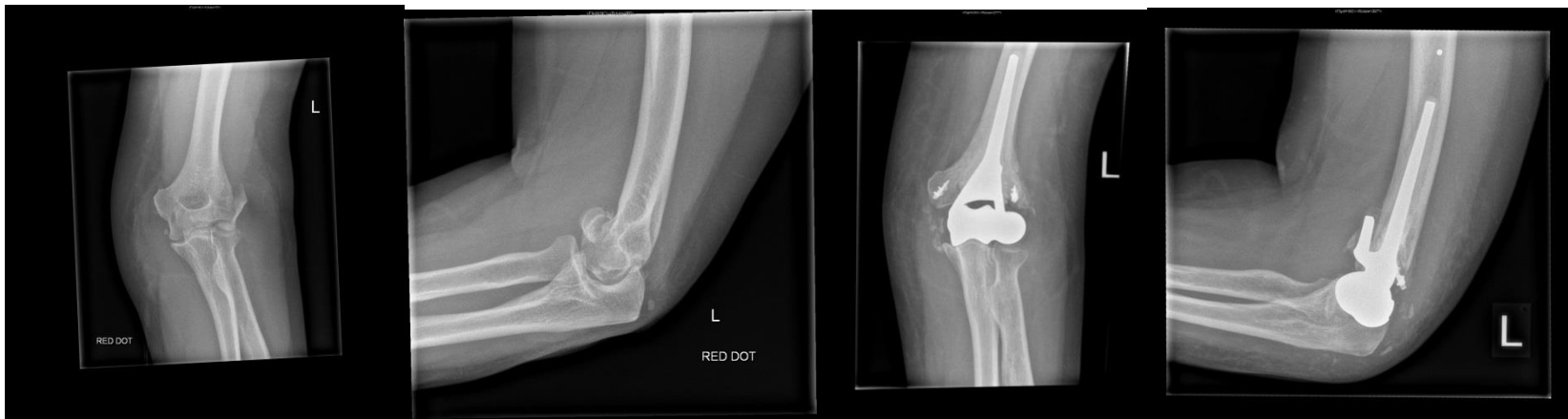


Munawar Shah






Rationale Of Arthroplasty

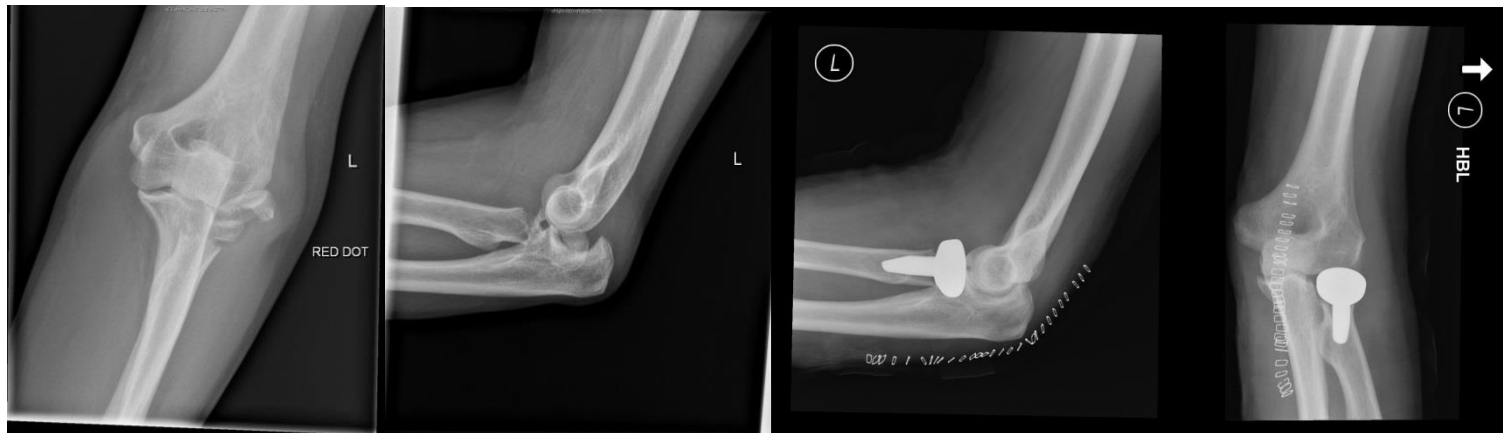

Munawar Shah






Rationale Of Arthroplasty

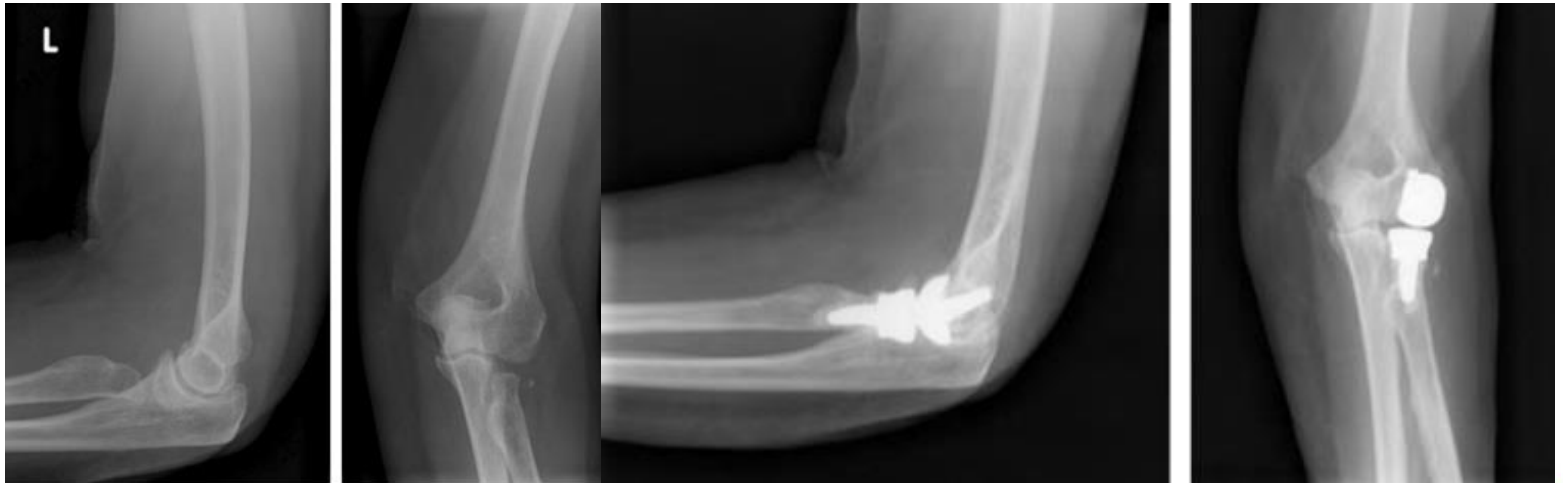

Munawar Shah






Rationale Of Arthroplasty

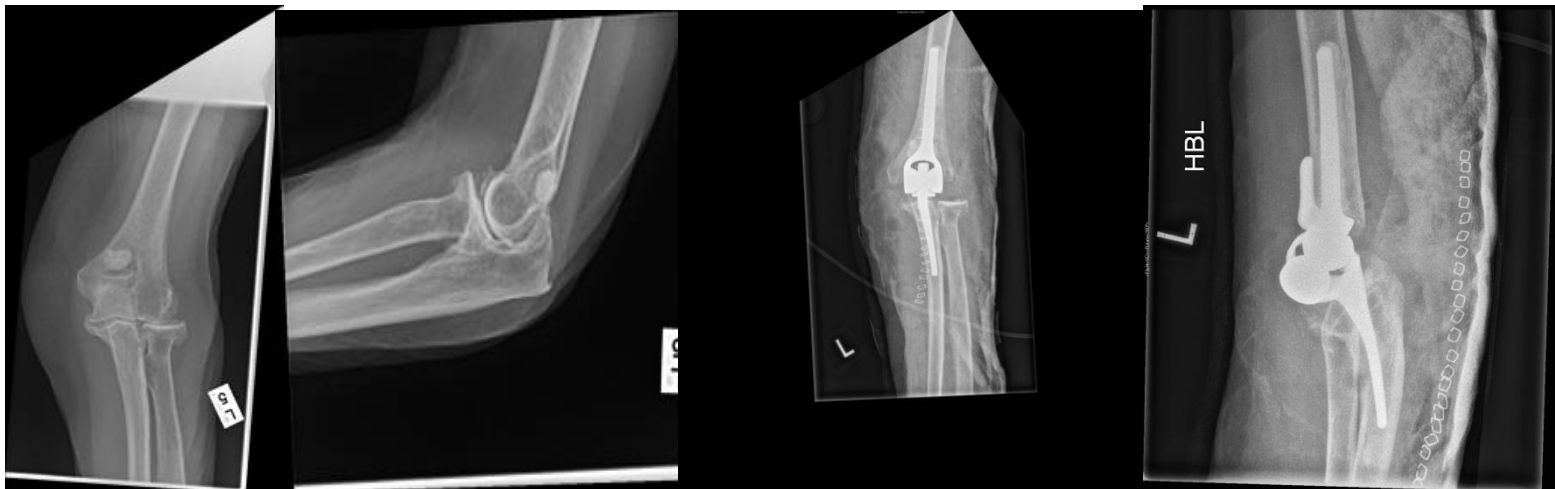


Munawar Shah



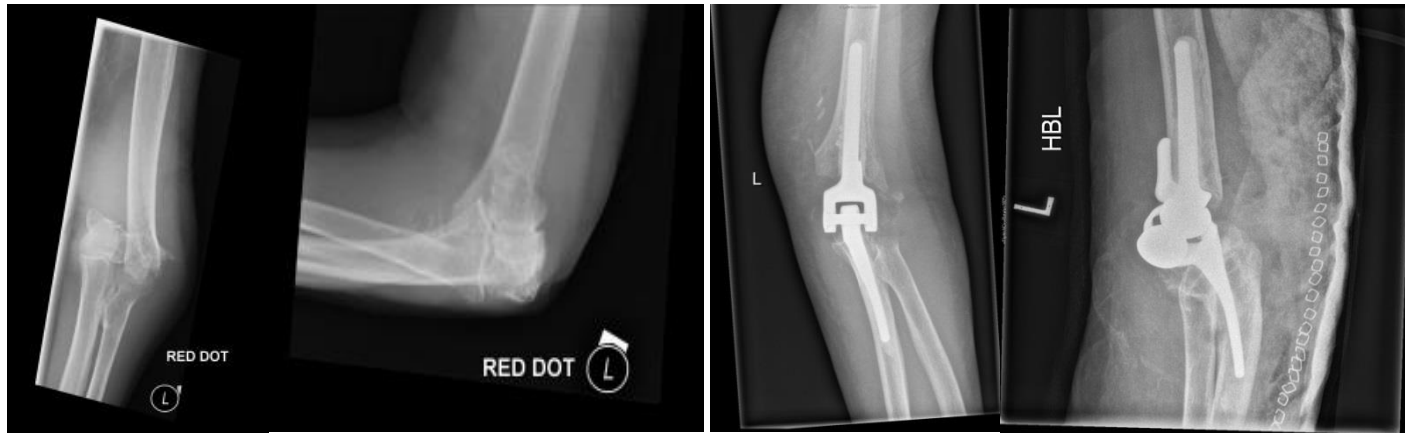


Rationale Of Arthroplasty






Rationale Of Arthroplasty

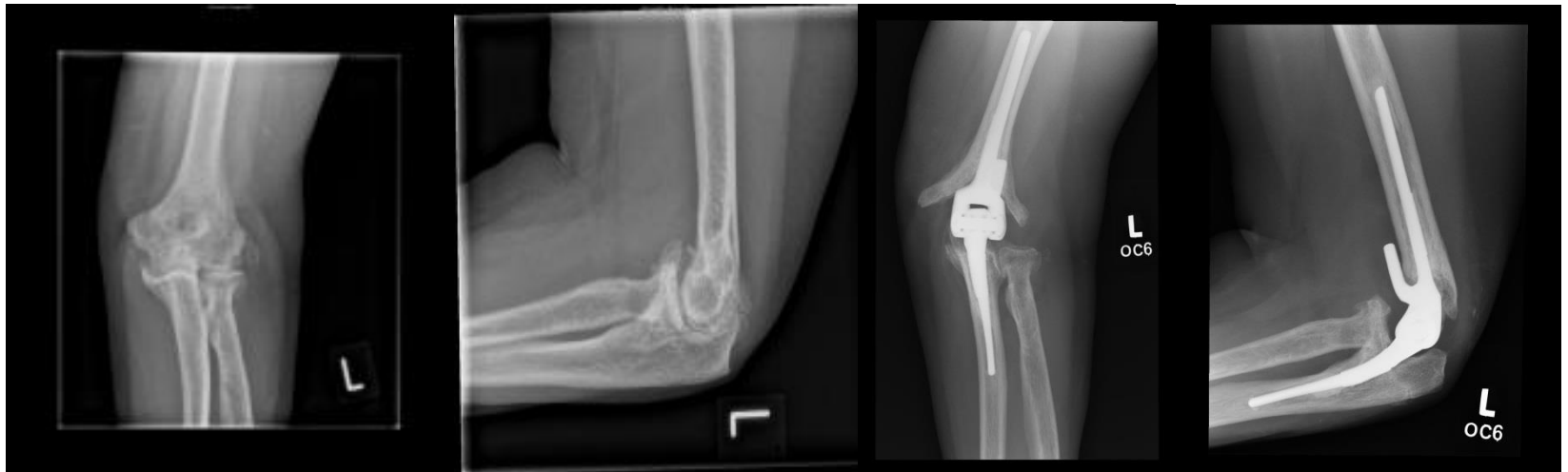

Munawar Shah






Rationale Of Arthroplasty



Munawar Shah





Rationale Of Arthroplasty

What is available


What is Evidence

What Do I do



Munawar Shah






Rationale Of Arthroplasty

Questions



Munawar Shah





Rationale Of Arthroplasty



Munawar Shah

