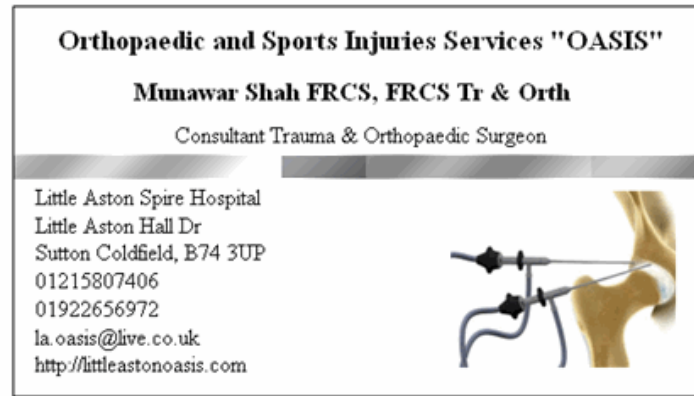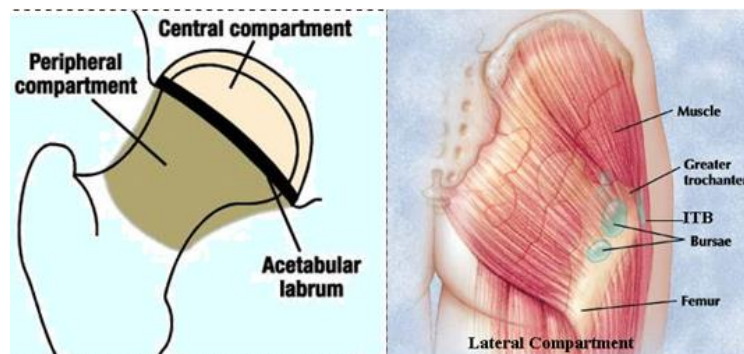


The Hip Joint has 3 compartments

Central

Peripheral

Lateral



The acetabular labrum is the dividing line between the central and Peripheral compartments in Hip Arthroscopy

The central compartment is the weight bearing part of the hip joint, with the corresponding joint surfaces of acetabulum and femoral head.

The peripheral compartment comprises the non-weight bearing part of the femoral head and the femoral neck up to capsule insertion

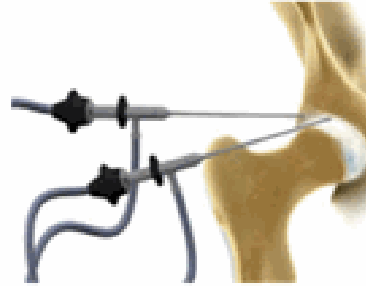
The lateral part comprises of the Peri Trochanteric space and its content

Orthopaedic and Sports Injuries Services "OASIS"

Munawar Shah FRCS, FRCS Tr & Orth

Consultant Trauma & Orthopaedic Surgeon

Little Aston Spire Hospital
Little Aston Hall Dr
Sutton Coldfield, B74 3UP
01215807406
01922656972
la.oasis@live.co.uk
<http://littleastonoasis.com>

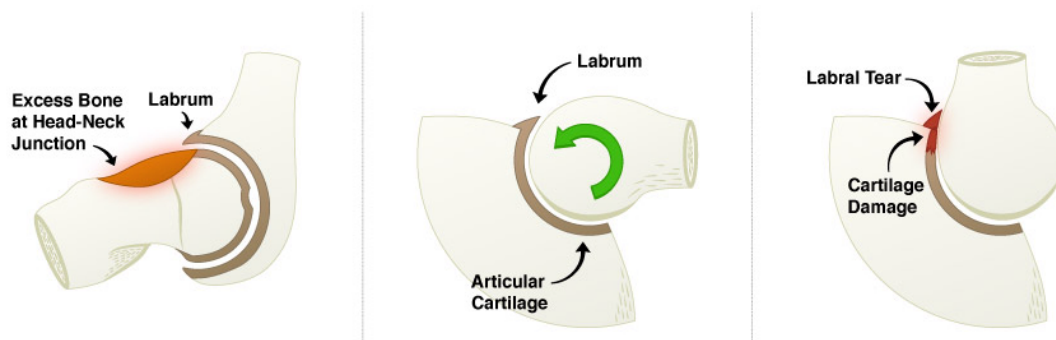


FAI

What is it?

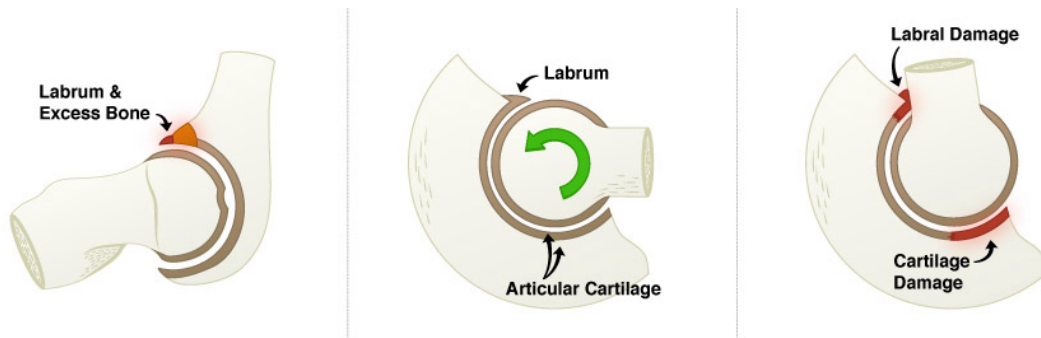
Femoroacetabular impingement or FAI is a condition of too much friction in the hip joint. Basically, the ball (femoral head) and socket (acetabulum) rub abnormally creating damage to the hip joint. The damage can occur to the articular cartilage (smooth white surface of the ball or socket) or the labral cartilage (soft tissue bumper of the socket).

FAI generally occurs as two forms: Cam and Pincer. The Cam form describes the femoral head and neck relationship as aspherical or not perfectly round. This loss of roundness contributes to abnormal contact between the head and socket.

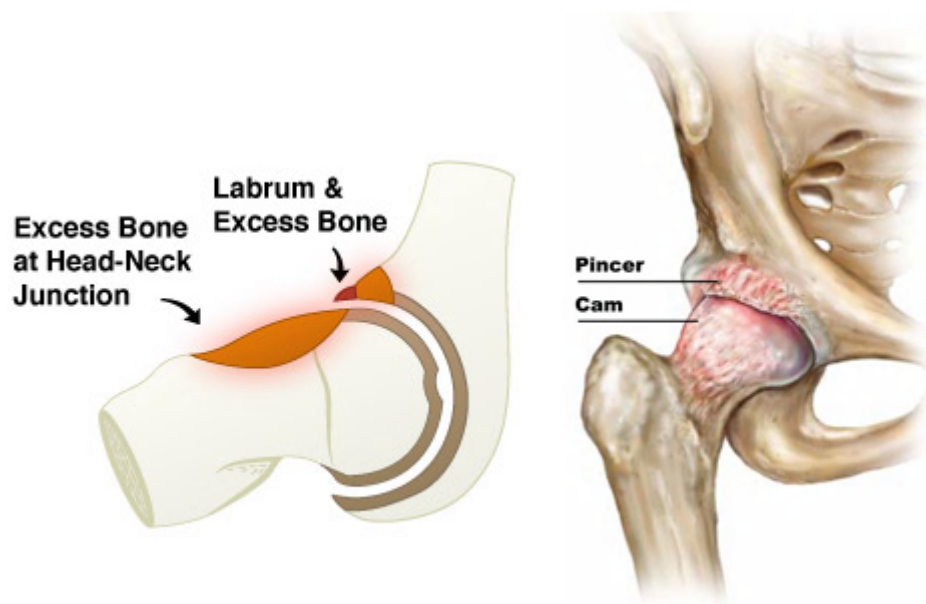


The Pincer form describes the situation where the socket or acetabulum has too much coverage of the ball or femoral head. This over-coverage typically exists along the front-top rim of the socket (acetabulum) and results in the labral cartilage being “pinched” between the rim of the socket and the anterior femoral head-neck junction.

The Pincer form of the impingement is typically secondary to “retroversion”, a turning back of the socket, or “profunda”, a socket that is too deep.



Most of the time, the Cam and Pincer forms exist together.



FAI is associated with cartilage damage, labral tears, early hip arthritis, hyperlaxity, sports hernias, and low back pain.

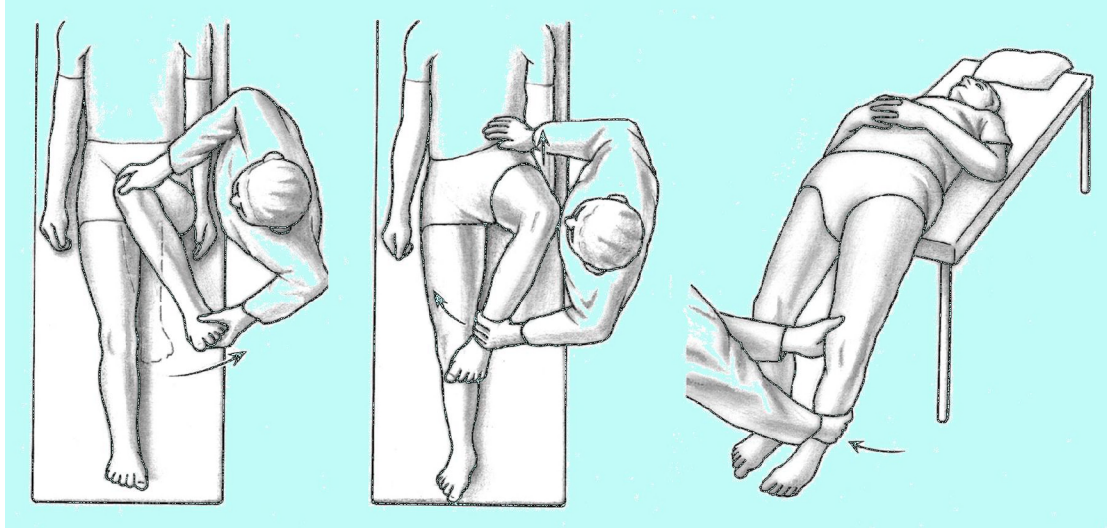
FAI is common in high level athletes, but also occurs in active individuals.

How is it diagnosed?

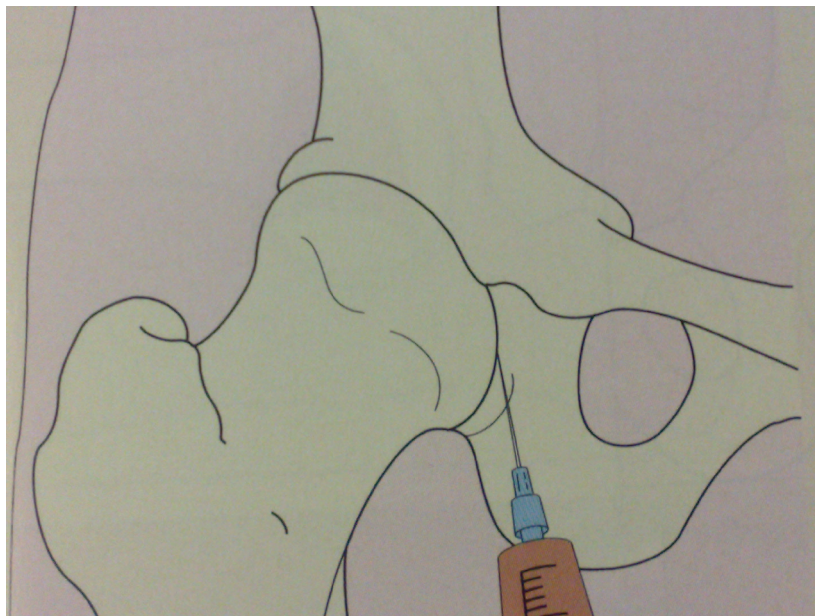
The diagnosis can be straightforward or a diagnosis of exclusion. Most patients can be diagnosed with a good history, physical exam, and plain x-ray films. A patient's history will generally involve complaints of hip pain (front, side, or back) and loss of hip motion. The physical exam will generally confirm the patient's history and

eliminate other causes of hip pain. The plain x-ray films are used to determine the shape of the ball and socket as well as assess the amount of joint space in the hip. Less joint space is generally associated with more arthritis.

Often an MRI of the hip is used to confirm a labral tear or damage to the joint surface. The MRI is most helpful in eliminating certain causes of non FAI hip pain including avascular necrosis (dead bone) and tumors.



The pain test typically involves placing a local anesthetic inside the hip joint with the contrast dye. Using the pain test helps assess whether the pain is coming from inside the hip joint



What other diagnoses might be confused with FAI?

- Hip Dysplasia (Adult Form)
- Lumbar Spine Pain (Low Back Pain)
- Lumbar Radiculopathy (Low Back Pinched Nerve, Low Back Facet Disease)
- Sacroiliitis (SI Pain/Dysfunction, back of pelvis)
- Trochanteric Bursitis (Outside Hip Pain)
- Piriformis Syndrome (Back of Hip Pain)
- Psychosomatic Pain Disorder (Stress Related Illness)
- Iliopsoas Tendinitis/Tendonitis/Tendinosis (Hip Flexor Inflammation)
- Groin Pull (Adductor Strain)
- Sports Hernia (abdominal muscle strain)
- Iliac Apophysitis (Front of Pelvis Pain)
- Quadriceps Hernia/Strain (Thigh Muscle Pull)
- Chronic Pain Syndromes

With what activities is FAI associated?

- Horseback Riding
- Yoga
- Soccer
- Ballet/Dance/Acrobatics
- Golf
- Tennis
- Field Hockey
- Rugby
- Bike Riding/Cycling
- Martial Arts
- Deep squatting activities such as power lifting
- Rowing Sports (Kayaking, Sculling/Rowing)
- Car riding (deep seated position)

Why does it occur?

No one knows if FAI is a condition that begins at birth (congenital) or develops during periods of growth (acquired). It is likely a combination of one's genetics and environment.

How did I get it?

Some experts believe that significant athletic activity before skeletal maturity increases the risk of FAI, but no one truly knows. Significant contact sports (i.e., football) are associated with Cam impingement.

Do I have arthritis if I have FAI?

Both plain film x-rays and MRI scans are an incomplete view of the cartilage inside the hip joint. It is possible and common to have good joint space on plain x-ray films and no signs of arthritis on MRI and still have significant loss of cartilage within the hip.

Do I have FAI if my hip MRI was read as “Normal”?

At times, an MRI will be read as “Normal” but the clinical history, physical exam, and plain x-ray films indicate FAI. In this situation, further investigation with an arthroscopic surgery may be needed.

My diagnosis was made after many years of hip pain, is that common?

Many physicians have heard of a hip labral tear but have not heard of FAI.

I’ve been treated for a labral tear with a hip arthroscopy. Can I have FAI, too?

Hip labral tears are associated with FAI. If you have had your labral tear treated and are still having pain, you may have unrecognized FAI. This FAI may accelerate the loss of hip cartilage leading to further degeneration. Labral debridement is not the same as labral repair.

Can my other hip be involved as well?

Yes, it is possible for both hips to have FAI.

I don’t have any pain, what should I do?

Some patients with FAI complain of stiffness and loss of hip range of motion without any significant pain. Progressive loss of motion in the hip can be associated with ongoing FAI.

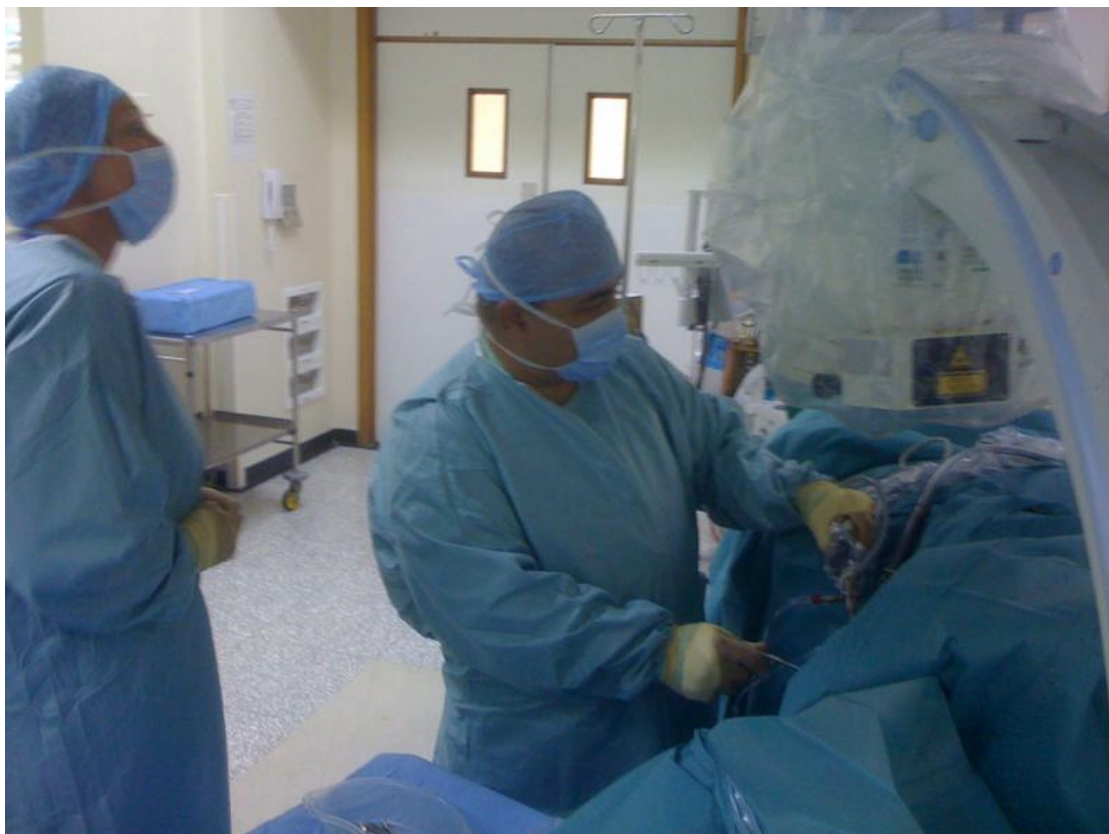My doctor says that FAI doesn’t exist, why?

Currently, three different opinions exist regarding hip pain and hip problems. The first is that all hip problems are generally mild and should be managed with nonoperative choices such as injections, therapy or rest. If there is severe hip arthritis, a total hip replacement is considered. The second is that hip problems often involve labral tears and that these tears can be treated by cutting out the torn tissue— usually with an arthroscopy. The third is that hip problems often involve labral tears and that these tears are often secondary to abnormal hip biomechanics such as the labrum getting caught by friction between the bone of the ball (femoral head) and the bone of the socket (acetabulum)- the condition of FAI. This third approach often leads to surgical treatment of the bone and soft tissue problems of FAI.

What are my treatment options?

Nonoperative management of FAI is possible; however, it involves a change in lifestyle from active to less active and a commitment to maintaining hip strength. Non-operative management may not change the underlying abnormal hip biomechanics of FAI.

Operative management of FAI can be addressed via hip arthroscopy or open surgery. In hip arthroscopy, the hip is distracted and an arthroscope is used to make an assessment of the hip joint and treat damage that is found through two to four 1 cm incisions. Often, all of the components of FAI such as the labral tear, damaged cartilage, and friction between the ball and socket can be treated through the arthroscope. Repair of a torn labrum as well as stimulating new cartilage growth (microfracture) are often possible with the arthroscopic approach. A hip arthroscopy involving labral debridement (no repair) and no bony decompression usually takes less than one hour. A hip arthroscopy involving labral/cartilage repair and FAI decompression may take between two and four hours, depending on the amount of work performed. Care must be taken to avoid damage to the hip's blood supply (the retinacular vessels) during the osteoplasty procedure.



Recovery time from most FAI surgical procedures is about 4 months to full, unrestricted activity. Your postoperative activity level will depend on your surgeon's recommendation, the type of surgery performed, and the condition of the hip joint at

the time of surgery. Revision FAI surgery may involve a significantly longer recovery.

What are the central, peripheral, and lateral compartments of the hip?

During a hip arthroscopy, the surgeon should visualize two compartments or spaces of the hip joint. The first space is the central compartment. The central compartment is composed of the surfaces of the ball (femoral head) and the socket (acetabulum) as well as the soft tissues (i.e., labrum). Procedures performed within the central compartment include treatment of the cartilage and labrum. The peripheral compartment is the remainder of the hip joint and refers to the area along the junction of the femoral head (ball) and femoral neck. Procedures performed within the peripheral compartment include treatment of bone spurs and the joint capsule. Both the central and peripheral compartments are within the hip joint capsule making them accessible with the arthroscope. The lateral or Peri Trochanteric compartment lies outside of the hip joint. The surgeon may enter the lateral compartment with the arthroscope to evaluate and treat disorders such as hip muscle/tendon tears, snapping hips, and hip inflammation (bursitis).

What are the main risks of FAI treatment?

- Complications from FAI hip surgery are uncommon but include the following:
- DVT (blood clot)
- Infection
- Hip Instability & Dislocation
- Femoral neck fracture
- AVN of the femoral head (dead bone)
- Heterotopic ossification (abnormal bone formation in soft tissues)
- Nerve injury (Sciatic, LFCN, Pudendal)
- Nonunion (open surgical dislocation only)
- Scarring/Adhesions

How long can I wait before seeking treatment?

Typically, FAI that produces symptoms should be evaluated for surgical treatment. A delay in FAI treatment may compromise the cartilage of the hip.

Can I be treated with an injection of medicine or good physical therapy?

Generally, FAI is a chronic condition that does not typically respond to hip injections or physical therapy over the long term. That being said, a good physical therapy program focusing on hip strengthening instead of stretching may be beneficial. In fact, the stretching associated with yoga may make the symptoms worse.

Can I just wait a few years and have a total hip replacement?

Yes. The postoperative rehabilitation of a total hip replacement (total hip arthroplasty) is significantly less than an FAI procedure; however, the lifespan of the replacement hip is shorter in younger patients. The same is true for a hip resurfacing type of procedure such as the Birmingham Hip Resurfacing Arthroplasty. Both the resurfacing arthroplasty and the total hip arthroplasty involve amputation of the diseased joint surfaces and replacement with man-made materials (i.e., metal, plastic, ceramic) which are subject to wear. The wear results in joint debris which may shorten the life of the replacement. Finally, the use of metal-on-metal hip bearings is controversial in women of childbearing age.

If you are interested in making an appointment to discuss a treatment, please click here to [contact us](#), or telephone 01215807406

Orthopaedic and Sports Injuries Services "OASIS"

Munawar Shah FRCS, FRCS Tr & Orth

Consultant Trauma & Orthopaedic Surgeon

Little Aston Spire Hospital
Little Aston Hall Dr
Sutton Coldfield, B74 3UP
01215807406
01922656972
la.oasis@live.co.uk
<http://littleastonoasis.com>

